

Hairballs as a Cause of Anorexia in Angora Goats

Sarah Baillie¹ and Kathy Anzuino²

¹Clyde Veterinary Group, Hyndford Road, Lanark, ML11 9TA

²School of Veterinary Science, Langford House, Langford, Bristol, BS40 5DU

SUMMARY

An unusual case involving three Angora goats with ruminal hairballs is reported. The presenting signs were anorexia and weight loss. The first two goats were treated medically and, after failing to respond, were euthanased on humane grounds. A definitive diagnosis was made after a post mortem was carried out on the second goat, which revealed seven hard balls containing hair in the rumen. When the third goat presented with similar signs, a rumenotomy was performed and five hairballs were removed after which the goat made a complete recovery. The causes of anorexia and weight loss in the goat, together with reports of cases involving hairballs in the goat and other species, are discussed.

CASE REPORT

Over a six week period, three Angora goats presented with anorexia and weight loss. The goats were kept as pets on a smallholding in central Scotland. In the summer they grazed freely in a paddock and in the winter they were housed and fed hay and goat mix. The first goat was presented for examination towards the end of the winter housing period. The goat, an adult female, was refusing to eat, had been losing weight over several weeks and was in poor body condition. There were no significant findings on clinical examination, there were no lesions in the mouth, the goat did not have diarrhoea and no other abnormalities were found. A definitive cause was not established and the goat was treated with systemic drugs to try and stimulate the appetite (Betsolan Soluble, Schering-Plough; Duphafal Extravite, Fort Dodge), an oral drench (Liquid Life-Aid, Norbrook) and antibiotics (Diphacycline 50, Fort Dodge). In spite of treatment, the goat continued to deteriorate and was euthanased on humane grounds. A month later, one of the two remaining goats, an adult neutered male, presented with similar signs and was treated with supportive therapy as before and antibiotics (Duphaphen LA, Fort Dodge). The goat was tested for Caprine Arthritis and Encephalitis (CAE), which occasionally causes chronic wasting in adult goats, and the result was negative. The goat failed to respond to treatment and was euthanased. A post mortem was carried out, which revealed a collection of seven hard balls, approximately 5cm in diameter, in the rumen (Figure 1). When cut open these balls were revealed to contain goat hair, which was enclosed in a leathery outer shell. The hairballs occupied most of the rumen leaving little space for food and therefore, were considered to be the cause of the inappetence.

Within a few days the third goat, an adult female, stopped eating and a decision was made to perform a rumenotomy. The goat weighed 28kg (Figure 2) and



Figure 1. The seven hairballs, lined up beside a 30cm (12") ruler, removed from the rumen of the second goat at post mortem. Each hairball was approximately 5cm in diameter and had a thin hard leathery outer shell.

was operated on under xylazine (0.2mg/kg, Rompun, Bayer) and ketamine (10mg/kg, Vetalar, Pfizer), with local anaesthetic along the line of incision and additional gaseous anaesthetic (Halothane, Merial) available as required. During the rumenotomy (Figure 3) five complete hairballs were removed along with several mats of hair. Post operatively the goat was given buprenorphine (10µg/kg, Vetergesic, Alstoe) for pain relief and antibiotic cover (Clamoxyl LA, Pfizer). The goat made an uneventful and full recovery.



Figure 2. The third goat just prior to surgery.

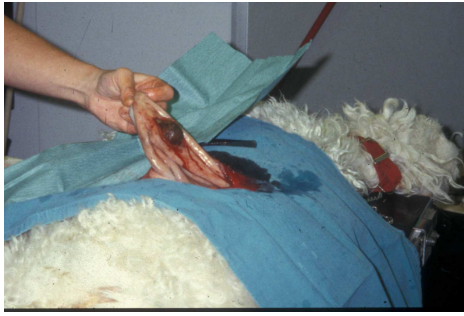


Figure 3. A hairball being removed from the rumen during surgery.

DISCUSSION

All three goats presented with anorexia and weight loss. A possible reason for these signs could have been mouth lesions or teeth problems. Alternatively, weight loss, with or without concurrent anorexia, can occur for a range of other reasons including nutritional deficiencies, gastrointestinal parasites and infectious diseases including Johne's disease, Caseous Lymphadenitis (CLA) and Caprine Arthritis and Encephalitis (CAE). On clinical examination, no specific explanation for the symptoms was apparent and no lesions were found. Laboratory tests on blood or dung samples would have helped to rule out some of the possible causes. However, only one sample was taken and this was from the second goat, which was tested for CAE and the result was negative. A diagnosis was made after a post mortem was performed on the second goat. The post mortem revealed that the rumen was full of hairballs, leaving little space for food, which could have explained the anorexia and weight loss.

Hairballs have been reported in a range of species including man, rabbits, cats, large and small ruminants. The presentation varies from asymptomatic to anorexia, weight loss, decreased passage of faeces and gastro-intestinal obstruction. Hairballs are also referred to as trichobezoars, a special kind of bezoar: a firm mass found in the gastro-intestinal tract formed by a concretion of swallowed material usually plant or animal in origin. In humans, a range of bezoars have been described with those formed from hair being one of the more unusual presentations (Zamir *et al*, 2004). Hairballs are not uncommon in rabbits and cats, both species being predisposed by their grooming habits, and most cases respond to medical management or resolve spontaneously. However, in the more severe cases the hairballs can cause an obstruction. A series has been reported in a colony of laboratory rabbits, where surgical treatment was required and large mats of hair were removed at gastrotomy (Gillett *et al*, 1983). In cats, swallowing of hair may become excessive in long haired breeds and when overgrooming due to skin irritation or stress. In the

most severe cases the hairballs can cause intestinal obstruction as described in five cats, and these cases either responded to surgery or were fatal (Barrs *et al*, 1999). Hairballs are not an uncommon abattoir finding in the abomasum of veal calves (Terosky *et al*, 1997). These form after hair is swallowed during excessive grooming and sucking. Hairballs are unusual in cattle given access to solid food unless skin diseases that cause irritation are present. Hairballs causing obstruction of the small intestine have been reported in two beef calves, presenting with anorexia and the absence of faeces, and both calves recovered after the hairballs were removed surgically (Abutarbush and Radostits, 2004).

Goats were first connected with the term bezoar in the 12th century BC after these stone-like concretions were found in the stomach of a Syrian goat. The word bezoar is derived from the Arabic meaning an antidote for poisons and those found in goats were considered to have healing properties and therefore, were much sought after for medicinal purposes. Surveys looking at the number of abnormal objects present in the gastro-intestinal tract of large and small ruminants have found a wide range of foreign bodies, including bezoars (Martins *et al*, 2004; Remi-Adewunmi *et al*, 2004). The incidence of foreign bodies is lower in goats than sheep, the former being more selective in their feeding habits. The commonest finding in both species is indigestible pieces of rubbish, especially those made of plastic. Hairballs appear to be very unusual but there is a report from India of a goat that presented with anorexia and recurrent bloat caused by a large number of hairballs and these turned out to be made of human hair (William *et al*, 2000). The goat grazed near a religious site where devotees shaved their heads. At surgery, 53 hairballs were removed from the rumen and reticulum and a further hair mass from the abomasum.

In the current case involving the three Angora goats, the hairballs were made of the animals' own hair and, as in most cases in other species, probably formed as a result of excessive grooming. Hairballs were found in the second and third goats (at post mortem and surgery respectively) but no definitive diagnosis was made for the first goat. The presenting signs were similar and, in the absence of another diagnosis, the assumption was made that this goat also had ruminal hairballs. There were no skin lesions on any of the goats and therefore, rather than excessive irritation and associated nibbling, a behavioural cause of overgrooming was considered more likely. After surgery, the surviving goat was groomed regularly and attempts were made to enhance the environment to try to prevent overgrooming and a recurrence of the hairballs. The goat lived outside all year round with a small flock

of sheep. A shed was available for shelter and the goat wore a coat during particularly cold periods. The goat lived out a full life, dying some years later in old age.

ACKNOWLEDGEMENTS

The authors wish to thank John Main and John Baillie at Clyde Veterinary Group, Lanark and the owners of the goats for assistance during the preparation of this case report.

REFERENCES

- Abutarbush, S.M. and Radostits, O.M. (2004). Obstruction of the small intestine caused by a hairball in 2 young beef calves. *Canadian Veterinary Journal* **45**(4): 324-325.
- Barrs, V.R., Beatty, J.A., Tisdall, P.L.C. Hunt, G B., Gunew, M., Nicoll R.G. and Malik, R. (1999). Intestinal obstruction by trichobezoars in five cats. *Journal of Feline Medicine & Surgery* **1**(4): 199-207.
- Gillett, N.A., Brooks, D.L. and Tillman, P.C. (1983). Medical and surgical management of gastric obstruction from a hairball in the rabbit. *Journal of the American Veterinary Medical Association* **183**: 1176-1178.
- Martins, A.M.C.R.P.F., Leme, M.C.M., Portugal, M.A.S.C., Baldassi, L. and Margatho, L.F.F. (2004). Presenca de Corpos Estranhos no Aparelho Digestorio do Bovinos. *Arquivos do Instituto Biologico* **71**(1): 83-87.
- Remi-Adewunmi, B.D., Gwang, E.O. and Oswinowo, A.O. (2004). Abattoir survey of foreign body rumen impaction small ruminants. *Nigerian Veterinary Journal* **25**: 32-38.
- Smith, M.C. and Sherman, D.M. (1994). *Goat Medicine*. Blackwell Publishers.
- Terosky, T.L., Wilson, L.L., Stull, C.L. and Stricklin, W.R. (1997). Effects of Individual Housing Design and Size on Special-Fed Holstein Veal Calf Growth Performance, Hematology, and Carcass Characteristics. *Journal of Animal Science* **75**: 1697-1703.
- William, B.J., Rao, G.D.J., George, R.S., Jayaprakash, R., Ameerjan, K., Dharmaceelan, S. and David, W.P.A. (2000). Rumenotomy and abomasotomy to remove an unusual number of trichobezoars in a goat. *Indian Veterinary Journal* **77**(4): 332-333.
- Zamir, D., Goldblum, C., Linova, L., Polychuck, I., Reitblat, T. and Yoffe, B. (2004). Phytobezoars and trichobezoars: a 10-year experience. *Journal of Clinical Gastroenterology* **38**(10): 873-876.